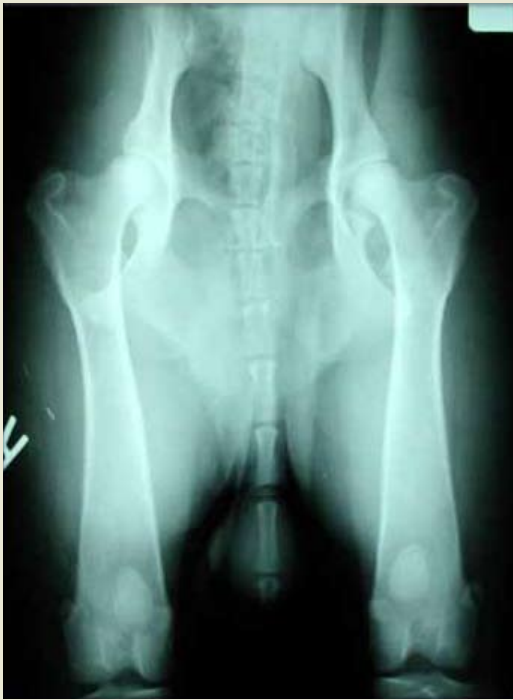

The Importance of Good Positioning on Canine Hip X-rays



By Ed Frawley



Leerburg Kennels

Foreword

When you view this eBook in PDF format. Click on **BOOKMARKS** on the top left side of your PDF reader, these bookmarks are eBook chapters.

[Leerburg Kennel](#) and Video is owned by Ed Frawley.

Ed has owned German Shepherds (GSD) for over 45 years. Since 1978 he has bred over 350 litters of German working bloodline GSD's. His dogs work in law enforcement, as S&R dogs, as competition Schutzhund dogs, and as family companions and protectors.

Since 1980 Ed has produced over 120 dog training videos and DVD's. He was a police K-9 handler for 10 years, competed in several dog sports, including AKC obedience and Schutzhund. In addition he has built one of the top dog training supply businesses in the world.

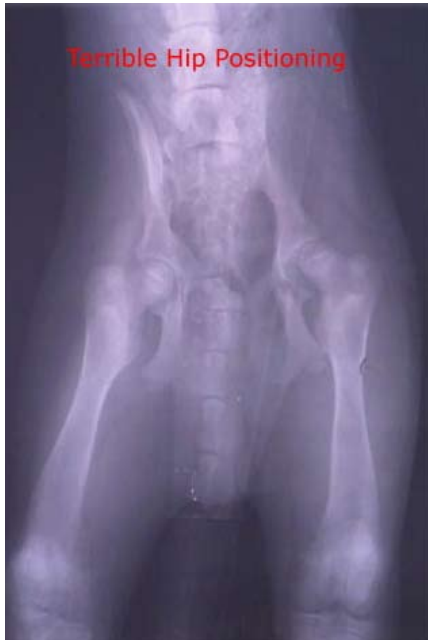If you go to the web site **Leerburg.com**® you will see that it has over 10,000 printed pages. The Leerburg Web Discussion board has over 10,000 registered members and over 120,000 posts in the archives. Learn to use our site search function.

The Importance of Good Positioning on Canine Hip X-rays

By Ed Frawley

I would like to thank Dr. Jane Brakken for help with my dogs and allowing me the use of her x-ray room to take these photos.

[Hip Dysplasia](#) (another article on the subject)



The positioning is so bad in this x-ray that the dog's owner should have refused to pay for it.

The purpose of this article is to teach the average dog owner how to determine if a hip x-ray is

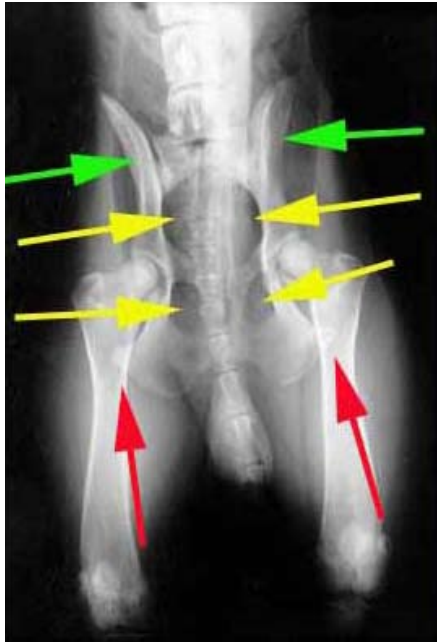done properly on their dog's hips. The article will demonstrate correct positioning and poor positioning. It will show 2 different sets of x-rays done on the same dog on the same day. One set has good positioning; the second set has poor positioning. You will see that with poor positioning, a dog's hips can look worse than they actually are. You will also see that no matter what you do with positioning you can never make a bad hip into a good hip.

The photo of the hip x-ray above (labeled good positioning) was done on a 10 month old German Shepherd from my kennel. While the dog is slightly angled on the x-ray plate, the positioning for the hips is pretty good. The photo below (the same photo as above) shows the various points on an x-ray to look at to determine if the dog was positioned properly.

Ed Frawley's Philosophy of Dog Training



Article



Good Positioning

Because this article is directed to the general public, I will not attempt to use the proper medical names for a lot of the terminology in this article.

The first thing to look at in an x-ray is to see if the legs come straight down from the hips with the knee caps square and looking alike. We don't want to see one leg straight and the other going off at an angle.

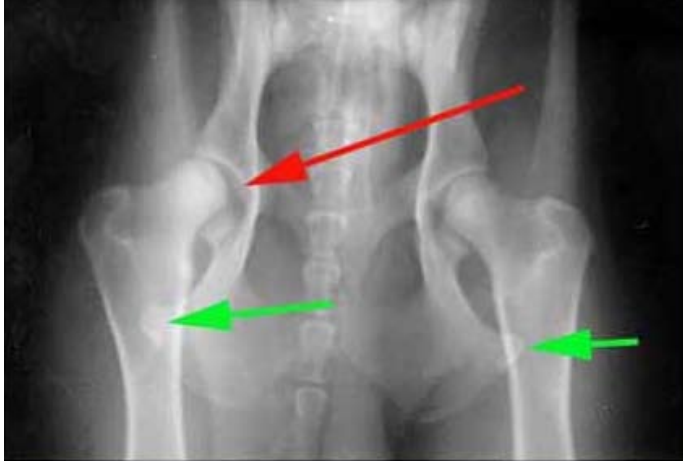
The above photo has 3 sets of colored arrows (green, yellow and red).

The green arrows above point to the bone that the hip socket is built into. These bones almost look like wings. You will notice that you can see

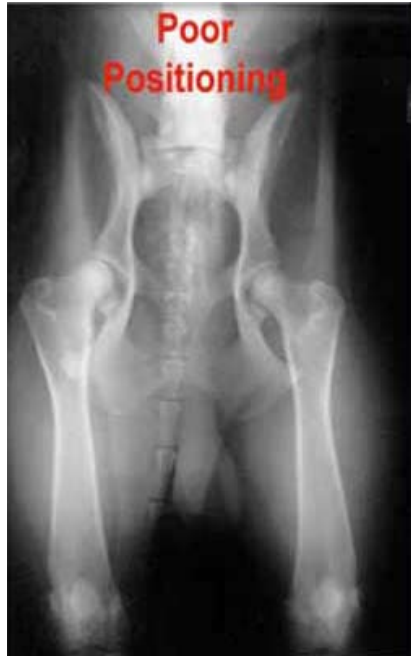more of the wing on the right than the wing on the left. When the position is 100% perfect, both wings will look exactly alike.

The yellow arrows point to holes in the bone structure. When the body positioning is correct the 2 holes on the left side are the same shape and size as the holes on the right side. The positioning is good on this dog, but not 100% perfect. That's why the holes on the right are slightly different than the left. This is most noticeable in the lower right hole being smaller than the left side lower hole.

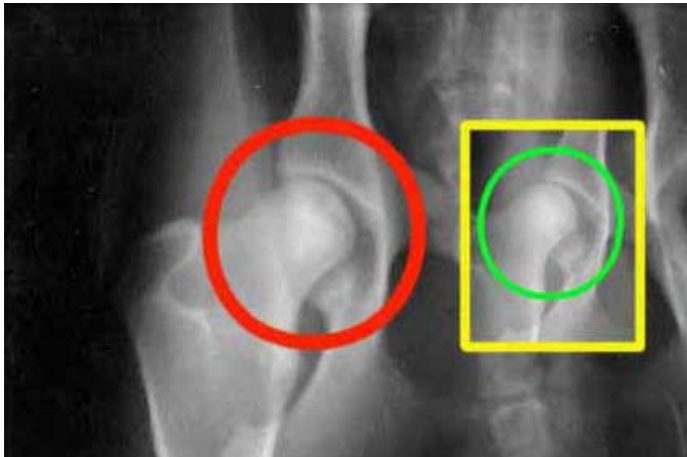
The red arrows above are the first things I look at when examining an x-ray. They point to the amount of pelvis bone that is covered by the leg bones on the x-ray. If you look at the pelvis, you can see that with the legs fully extended straight down, the legs overlay the very corners or tips of the pelvis. You can see the overlap through the leg bone. The picture above shows an even amount of overlap on both sides of the pelvis. The photo below shows a much larger overlap on the left of the screen than on the right of the screen. This is poor positioning.



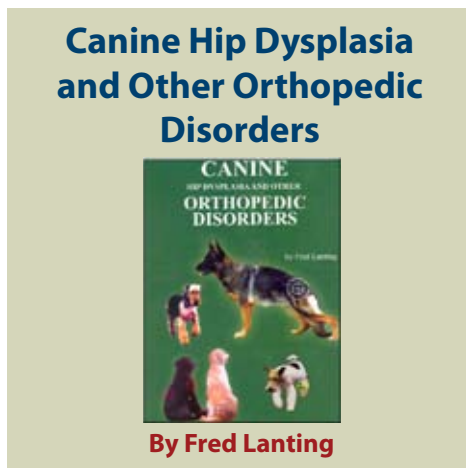
The photo above is the same dog only a different x-ray than the first one. This second x-ray has poor positioning. Notice how much more the pelvic overlaps the leg bone (the green arrows) on the left than on the right. The result is the hip is pulled further out of the socket (the single red arrow) because of poor positioning.



The x-ray above is an example of poor positioning. Again this is the same dog as the good x-rays above. The dog is rotated. You can see the upper right hole through the body cavity is noticeably smaller on the right than the left. The pelvic wing under the leg is noticeably larger on the left than the right.



This photo graphically shows the results of poor positioning. This photo shows the same hip joint on the same dog x rayed on the same day. The hip in the red circle is a much deeper seated ball in the socket than the picture in the yellow box (which had poor positioning to produce these results).



Some people ask how the difference can be so dramatic. My feeling is that these are young dogs. They have loose ligaments (just like a young child). If I took some of the falls that my eleven year old does I would have numerous broken bones. It's the same with our dogs. As they get older their ligaments are not as loose and they will probably not stretch as much. There may not be as much of a difference in older dogs. But at a young age positioning is critical.

The importance on positioning is often overlooked by the vet that is shooting the films. There may be a number of reasons for this:

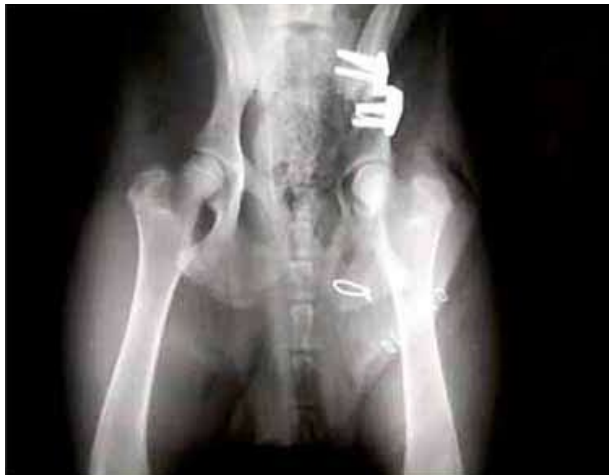- It could be lack of experience doing hip x-rays.
- It could be a money issue with him. To shoot another x-ray because he made a mistake costs him money.
- It could be that by the time the x-ray is developed and he realizes the position wasn't that good, the animal is gone or awake from being knocked out.

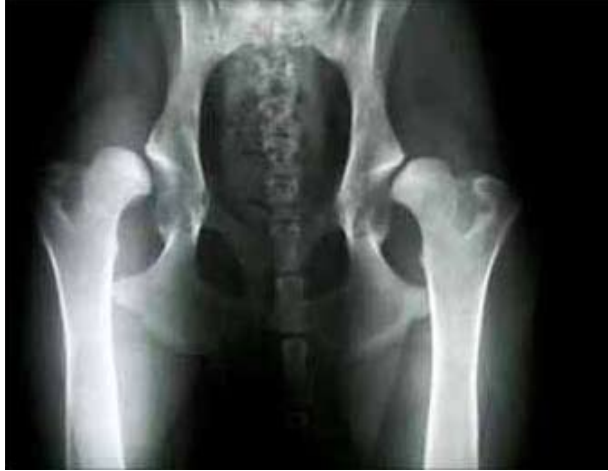In my opinion, none of these are good reasons. To get good x-rays you have to have a good vet. I have a couple of local vets that are very good with x-rays. If they make a mistake they re shoot it at their expense. We just recently started to see the OFA send x-rays back to the vets because of poor positioning. When this starts to happen on a

consistent basis, we will start to see much better x-rays of the dogs.

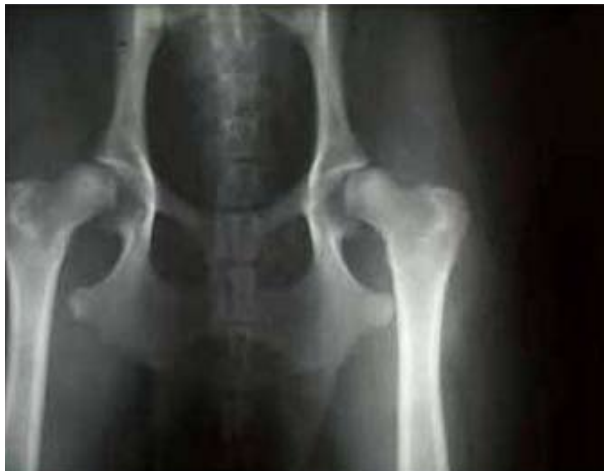Over the years I have seen some absolutely terrible jobs of x-raying dogs. As time goes by I will continue to add poor x-rays to this article so people can learn what to look for.

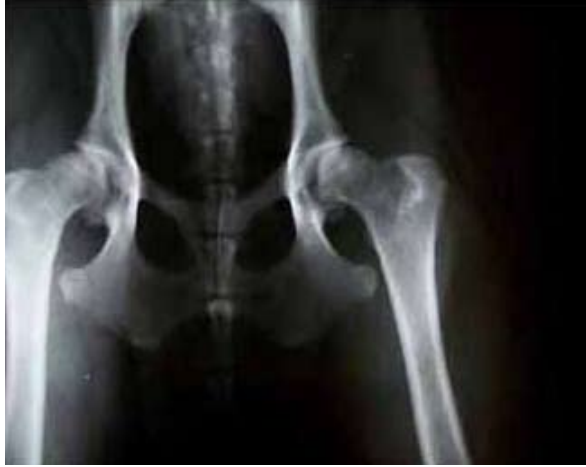There are several operations that are being done today to correct a bad hip and allow the dog to live a normal life. The x-ray below is an example of what a hip can look like after the operation. This operation needs to be done at an early age.





This is a photo of a very bad set of hips. It's questionable if surgery could even correct this dog's problem. These are hips from an 8-month old German Shepherd that came from a back yard breeder. A dog with hips like this should be put down. It is facing a life of pain.

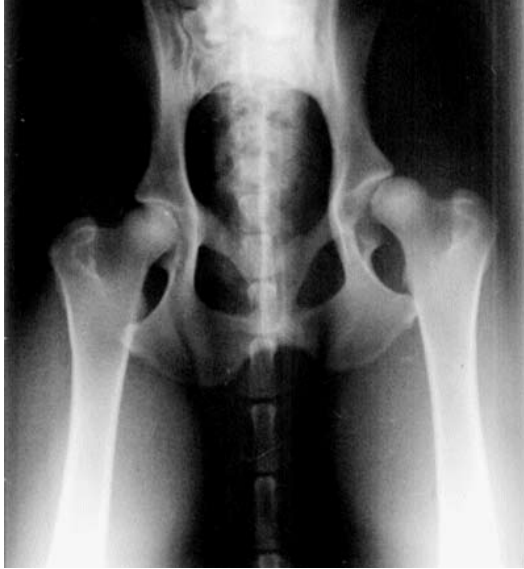



The 2 x-rays above are of the same dog (a Border Collie). The top x-ray was taken at 8 months of age. The lower x-ray was taken at 4 years of age. This can give you an idea of what will happen to bad hips over time. Notice the thickening of the neck of the joint. The ball also shows signs of arthritis. This dog is living as a house dog where her exercise is monitored. When the pain gets bad she is given Rymadil and this seems to make her comfortable.

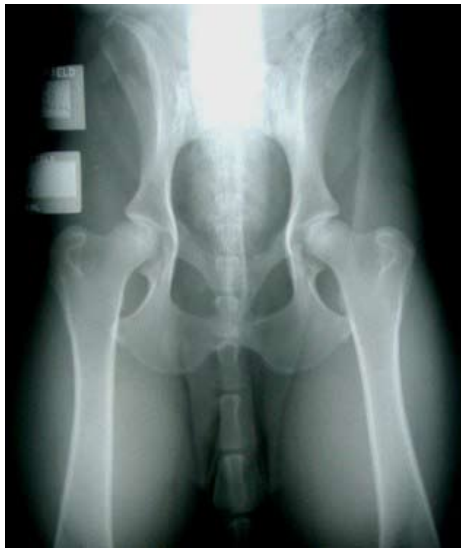Same Dog 9 Months Apart

Here are photos of 2 different x-rays taken of the same dog taken 9 months apart. The first x-ray showed the dog having bad hips. If you look closely you will see the positioning is not correct. It's not that bad but it is also not perfect.



Taken Sept 2002

The second photo below shows the dog with good hips. The positioning has been improved and this has made a big difference in how the x-rays look.



Taken June 2003

My advice to anyone would be to not accept incorrect positioning of any kind. Discuss this with the vet before the x-ray. Show him this article if he has any questions. I personally will not pay for a bad x-ray.

I recently had a similar situation with a young dog that I x-rayed at 6 months. The picture did not look that good but the rest of the litter was good. So I redid the x-ray at 9 months and saw an entirely different x-ray. The dog will pass OFA if the x-ray stays the same.

I would also recommend swimming a dog to build muscle mass if there is any question on the hips. The better condition a dog is in the better chance of a good x-ray. I have a friend who has watched the OFA on a yearly basis. She has noticed that there are more bad hips in the winter months than summer months.

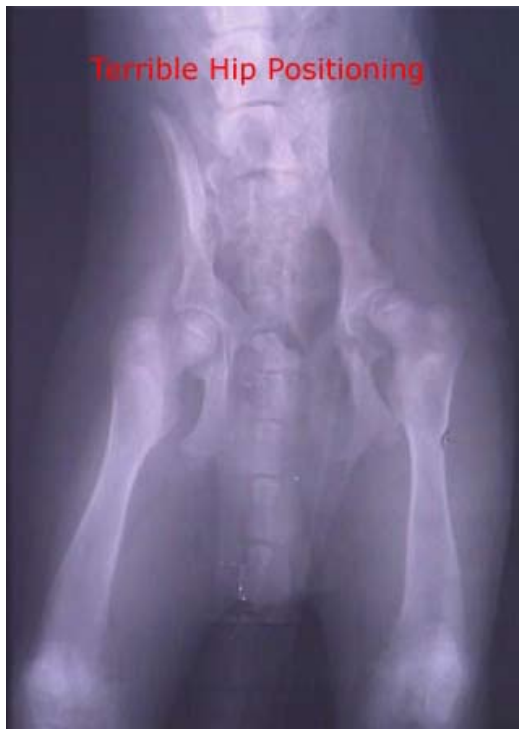For me this translates into dogs not being in as good physical condition in the winter months as the summer. In the future I will not be x-raying dogs in the winter. I will also make sure that my dogs are in excellent condition when the x-rays are taken.

Hip Dysplasia and the SV

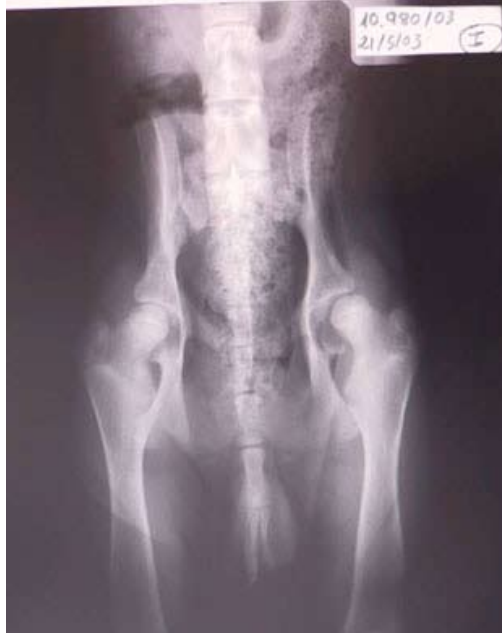

Article

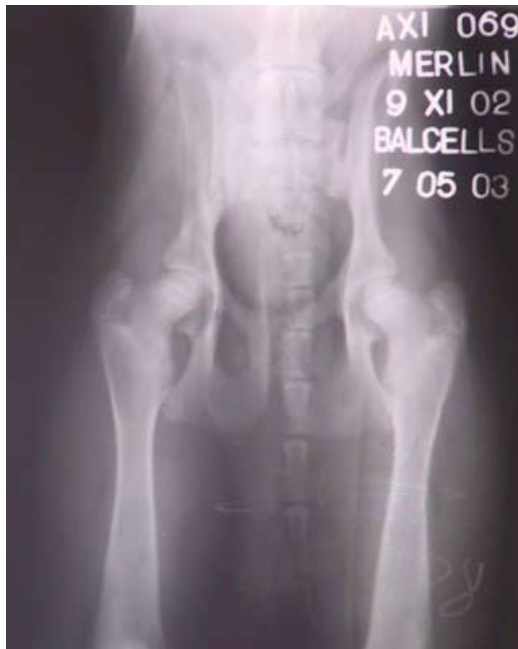The Following are 3 x-rays of the same dog done at different times.



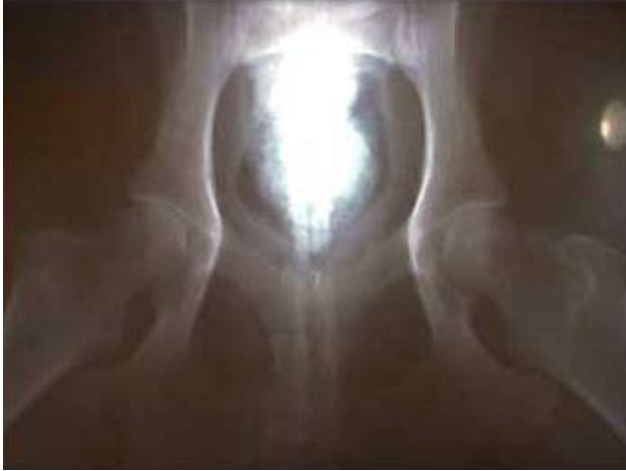January - 2003



Positioning still not correct - look at right hip



**May 2003 Better but not perfect. Look at the right hip
in all three shots.**



This is the worst case of hip positioning that I have ever seen. The Vet that took them and gave them to the customer should get out of the business.

What you can do to prevent bad hips

With all this said - if you are reading this article and are asking yourself what you can do to make sure your dog has healthy hips? The SV in Germany (the German Shepherd Dog Club of Germany) has proven that genetics is only responsible for about 25% of the bad hips in dogs. This means that 70% to 75% of the bad hips are caused by environmental issues.

There are things that help:

1- Keep your dog thin - when I say thin I mean you need to see a definition between the ribs and loins of your dog. I cannot stress this enough.

The more weight a dog carries the more pressure on the hips. This is extremely important when the dog is growing (between 8 weeks and 18 months)

2- Do not over exercise your young dog. DO NOT TAKE A PUPPY JOGGING!!! Not until it's older than one year of age. Over exercise is the fastest way to destroy hips.

3- [Feed a quality all-natural diet.](#) If you don't want to feed a raw diet at least feed it an all-natural commercial diet. I have an article on the various commercial kibble - we also sell one of the best called "[Honest Kitchen](#)" We have fed this for years and feel that it's the best we can find.

We stress the diet with our puppy customers and it has made a huge difference



4- If you have a question about subluxation in a young dog - SWIM the dog!! Take the dog swimming every day for 3 or 4 months before you have x-rays taken. Swimming is the best exercise you can do for a dog. It is way better

than jogging the dog. When you stop and think that subluxation means the head of the femur is loose in the socket - does it not make sense to exercise the dog so the muscles and ligaments tighten up the dog as much as possible.

5- We give our dogs 99% Glucosamine supplements - [we also sell it to customers click here for details.](#) The fact is I take the same product myself (in orange juice)

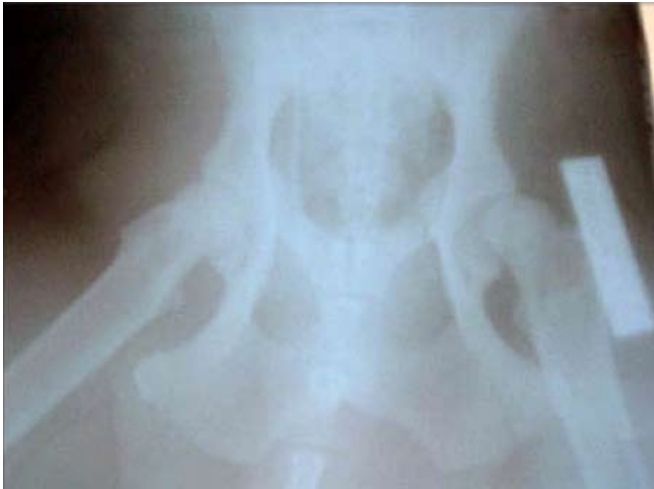The fact is you can do all of the things mentioned above and still get bad hips. That's the sad thing. I have bred over 350 litters in 30 years, the dogs I breed have good hips 6 to 10 generations and we will occasionally get a bad hip. I will say that the percentage of hip problems in our kennel is much, much less than breeders who do not follow this protocol.

Syn-Flex Glucosamine Complex

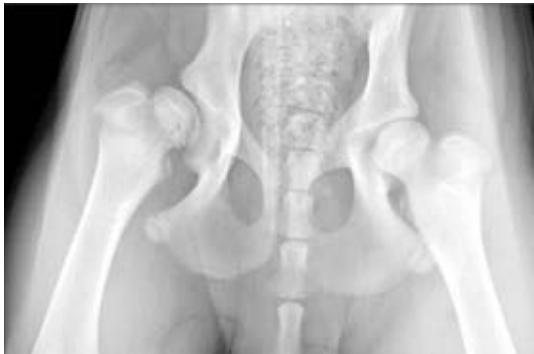

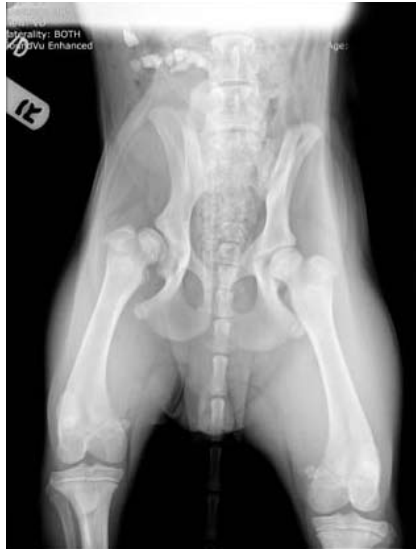Part of a healthy diet!

THE WORST POSITIONED HIPSI HAVE SEEN



The x-ray above was sent to me in Feb 2006. It is the worst example of hip positioning I have ever seen. The Vet that took these should give up his day job and seek another career.





The above 2 pictures are of awful positioning. The hips are bad however, and no matter how they were positioned it would not have made them look any better.

Emails

Comment on the Hip X-ray article

Ed

Thank you for that article on hip positioning. I have an associate degree in Veterinary technology that I received in 1990; radiology has always been a passion of mine. You are so correct!!!! I have worked for so many vets who do not know how to take proper x-rays and even worse they hire people off the street to do it

for them and instead of training them the right way to do it or pay a little more money for an educated person to work for them. They count on owners being un-educated. I have been telling people this for years. I breed Labradors now, and my vet and I have a good understanding she takes 2 x-rays of hips for me tells me her opinion then give me x-rays and I can choose which one I want to send to ofa. But I must say she does a great job.

Thanks again for educating the public and I think everyone should get a 2nd opinion before doing major hip surgery. AND I SO AGREE with you I have seen dogs with moderate hips dysplasia not show any signs of weakness simply from being able to swim to build there muscles. Swimming Dogs is the best physical therapy.

Karen

TESTIMONIAL on hip-x-ray article

October 15, 1998

My name is Goran Persson and I'm living in south Sweden, I have been struggling with the result of bad position with the Swedish Kennel Club.

After reading your article and taken part of your excellent photos I have succeeded to get a veterinarian to take some new x-rays and our

champion Parson Jack Russell Terrier dog has been upgraded from mild hip dysplasia on one hip and excellent on the other to excellent on both hips. I would like to thank you for the help that your article have given me.

I'm planning to write an article in our club magazine and also in the Swedish Kennel Clubs monthly magazine and if I can use your photos it will be very helpful for my work. I will also like to refer to your article if you don't have any objections about it.

All the best and thank you again.

Yours,

Goran Persson

QUESTION:

Hi Mr. Frawley,

Over Christmas break we noticed our dog, Abbey (one year old yellow lab) had a limp on her back right leg that wouldn't go away. I took her into the vet and the vet established that at least one hip, more than likely, had displaced. We brought our dog in to our vet for x-rays and we were told, "both of her hips show a loose joint on palpation. Knees tight. On the x-rays her left hip is nearly out of place. The right side is in place but is also affected. At this time there are only a few minor

changes associated with chronic dysplasia." We were told she would be, "a good candidate for any of the corrective surgical procedures for hips." I started doing some research and luckily came across your article. After reading your article, I tried to determine whether or not her x-rays were bad. In the x-ray, her legs do not appear straight, one is bent more than the other. There is also no overlap with the pelvis bone and the leg bone at all. There does however appear to be the same amount of space between the tip of the pelvis bone and leg bone. Also, the holes in the bone structure are fairly symmetrical.

Our vet is in Delaware and a surgeon was recommended who is also in Delaware. I feel really confused about what to do. We were both shocked because our dog came with papers. I beginning to realize that doesn't mean a whole lot. I am just going to do what I need to on my end to make sure our dogs parents don't breed again. If you can give any advice I would greatly appreciate it. I hope to hear from you.

Sincerely,
Holly Yoder

ANSWER:

The fact that your dog has papers means absolutely nothing in terms of hip dysplasia. The AKC is a joke in that regard. They do not require dogs to have their hips x-rayed before they can be bred. This organization holds itself up as the

ultimate supporter of pure bred dogs yet they allow people to breed dogs with bad hips. It's a money thing and nothing else

With that said I cannot comment on what you should do. It sounds like the x-rays are good. You need to follow the advice of your Vet if you think he or she is reputable. It sounds like this is the case.

The smartest thing you can do is to keep this dog skinny. Skinny to the point of seeing a definition between the ribs and the loin. Skinny to the point where people (who know little about dogs) tell you your dog is too thin. Not only is this healthier for the dog it is much easier on what's left of the hips.

Then allow this dog to swim as much as you possibly can in the summer. Swimming is the best exercise there is for dogs with bad hips. It builds muscle without hurting the skeletal structure.

I would also highly recommend an all-natural diet. You can read about it on my web site. Look in the list of training articles on my web site at <http://leerburg.com/articles.htm>. Keep the dog on Glucosamine. We just added a [liquid Glucosamine](#) product to our product line. The liquid far out performs powdered products. The body absorbs it much better than the powder.

Good luck with your dog. I hope it turns out OK.

QUESTION:

Ed,

I wish I would have taken your article in to my vets this morning. I had my seven month old German Shepherd spayed today along with hip x-rays. The vet said the hips were in very poor condition and showed the x-rays. He said they looked so bad that he re-x-rayed her standing when she was awake and they were just as bad. Your article doesn't mention anything about hip x-rays and the dog standing up. What is your thought on that?! At first I was in an absolute panic. He said she'd need major hip surgery in three months if they didn't improve. Now, I'm researching it a bit more before I do anything drastic.

-- Thanks Shelly

ANSWER:

Find a new Vet. Seriously. In 42 years of owning GSDs I have never heard of hip x-rays when a dog is standing. This Vet is full of you-know-what.

You have the photos of correct positioning from this article I wrote. You do not have to be a Vet to figure out if the guy gave you a good set of x-rays.

QUESTION:

I have a 10 week old GSD and I took him to the vet for the first time and the vet did some sort of pulling test on the dog's legs to check for a hip problem. My pup yelped loudly and now the vet wants to do x-rays and thinks there is potentially a problem. The vet says that if there is something wrong they are going to fuse the bones together to prevent future problems.

Do you see anything wrong with this? Any concerns or comments would be appreciated.
Thank You

ANSWER:

Find a new vet- seriously!! This guy is full of beans. I have bred dogs for 30 years – over 340 litters. This is total BULL on a 10 week old puppy. This is a perfect example of a crooked vet trying to get his hand in your wallet.

TESTIMONIAL:

Ed,

Hope all is well. I sent you a message about a year and a half ago reference my dog's hips. The vet was saying he was a candidate for the Pen hip surgery and his hips were not very good... this evaluation came after a physical evaluation at 4 months of age. Your reply was to get a new vet and tell her to get her head out of her ass.... I took

your advice. I just received my dog's OFA results...
OFA Good. Thanks for your advice.

PS My dog is out of Valco Vom Leerburg (Dago)
- Jon Wycoff, and Zalinde Vom Leerburg (Frankie)
- Jon Wycoff.

QUESTION:

Hi Ed,

We would like to get your opinion about something our vet suggested. She would like to do a PennHIP on Dita (Hilde X CJ) and possibly a Juvenile Pubic Symphysiodesis if required. Is this a viable course of action or a load of crap? We want to do what is best for Dita in both the short and long term.

Thank you, Rip and Denise

ANSWER:

I have written about PennHIP on my web site. I am not a fan of it and don't recommend it. It basically measures the degree of laxity in the hip to determine if the dog will be Dysplastic.

The way I look at this is that young dogs are like young people. They are loose ligamented. I was when I was young and I used to throw my knee caps out. As I aged my ligaments tightened and the problems disappeared. I believe the same thing happens with dogs – they are loose

ligamented – not all, but a lot. As they age they tighten.

When a PennHIP is done on a loose ligamented dog it's my opinion that this can give you a false negative reading.

We will do normal preliminary hip x-rays at 6 to 10 months of age. When we do the OFA we never do it when a female is in season and we try and swim them every day (not run them) for a month before the x-rays to tighten them up).

I have been breeding dogs for almost 30 years – and never heard of Juvenile Pubic Symphysiodesis.

So I would have to wonder if this Vet was trying to get into your wallet.

COMMENT:

Ed,

I was sent your site by a friend who does rescue work with me. Overall the info is very good. But the last letter about the JPS surgery is incorrect. It is the newest surgery for hip dysplasia. It was developed at the University of Wisconsin. It is very, very new. The long term studies are still being done.

I am sorry you have such a high disregard for veterinarians that you deem it a money making

scheme by a vet vs. sound medical advise.
Stereotyping vets as money grubbing is as bad as someone saying that breeders do it for the money.

There are many of us out there that do this work for the love of animals....I do not disregard your site as full of quackery because you are selling your products....

I work hand in hand with my clients to get the best for their pets.

Sue Fluhr D.V.M.

ED'S RESPONSE:

You are in the minority.

I am sorry to say this but my feeling is that the vast majority of Vets are more concerned about making money than the care of dogs. Pushing yearly vaccinations is the perfect example. It's complete BS and anyone who defends that position is full of beans. Pushing Science Diet over an all-natural diet is just another BS move –

Your profession has a public relations problem. The vast majority of Vets are arrogant asses that assume their customers are stupid (notice I said customers) If you have not figured this out then what can I say. Just today I made the decision to start a STUPID VET section.

I happen to have a very good Vet – she is honest

about things she does not know and we work together to keep our dogs healthy.

QUESTION on Hip Problems:

Hi Ed,

I really need your advice on something. My Rottie pup is 15 months old and in the past 3 months is showing signs of hip dysplasia ie: funny looking walk, wont jump up into jeep etc. Our breeders have a hip guarantee in their contract and I inquired about the guarantee tonight. They told my wife and I that we would have to pay for the X-rays (no problem) and that if she was indeed dysplastic then we could give them our dog for a new puppy or they would give us \$300 dollars towards surgery. My wife and I find this policy to be quite unrealistic as we absolutely love our dog and would never give her away just because of her hips. I put a deposit down over two months ago for the first male in a litter to be born in two weeks with the same breeder. Would it be unreasonable for me to ask for the breeder to absorb the costs remaining on that dog? If I traded mine in for a puppy, they would be down a pup anyways, and would probably put mine to sleep, so what's the difference? What do you think of this breeder's policy? Am I being unreasonable? My wife doesn't want me to even buy the dog off of them because of their policy. I am aware of the risks even if the dog's parent's hips are certified (in this case they are) and have

tried to convince her that it is just bad luck on this one. I respect your opinion and recognize your long term experience as a breeder. Where do I go from here Ed?

Your response is greatly appreciated,
Brody

ANSWER:

You can't form any opinions until the dog is x-rayed. Read the article I wrote on correct hip positioning for hip x-rays. It's very good.

Right now you don't even know if your dog has bad hips. He could have pulled a muscle.

HOW DO I PICK A VET?

Hi I have a question. I want to get my German Shepherd Hip's x-rayed. We are going to breed her with a stud but they want OFA "good" hips. We live in NY and I was reading about the experiences you and people were having about wrong positions, lying Vets and etc. I wanted to know how you can know if they are experienced. We go to a Vet clinic here called Valley Cottage we called and asked if they do x-rays on hips. They said yes. It is \$293 for the x-rays and \$43 for the certificate. Is it reasonable, the price? That's a lot of money for not doing the job right... They seem good with dealing with animal problems but reading your article has made me wonder how do I know they are good with the x-rays of

the hips. I wanted to know if you recommend anybody in NY or NJ that is very experienced with this type of job. Thank you Ed.

Amanda

Ed's answer on picking a Vet

This is a complete RIP off keep looking. \$293.00 for hip x-rays is ridiculous

Print off my article. Take it to where you are going to have the x-ray done (not this place) ask them if they will guarantee correct positioning like in this article. If they can't or won't guarantee then don't give them your business.

Regards

Ed

Where To Go From Here

All Natural Diet for Dogs



Article

Naturopathic and Healthcare Products



Part of a healthy diet!

The Theory of Corrections in Dog Training



Article


Basic Dog Obedience

\$40.00 +s&h




4 Hours Long

Download our New Catalog



With Active Links!

Leerburg eBooks



LEERBURG
Dog Training Podcasts